



SOUND DIAGNOSTICS OF NORTHWEST FLORIDA

1414 Clayton Road
Chipley, Florida 32428
850-258-1580

Results of Carotid Ultrasound

Patient Name: _____ Date: _____
 MR# _____ Age: _____
 Date of Birth: _____ Diagnosis: _____
 Referring Physician: _____

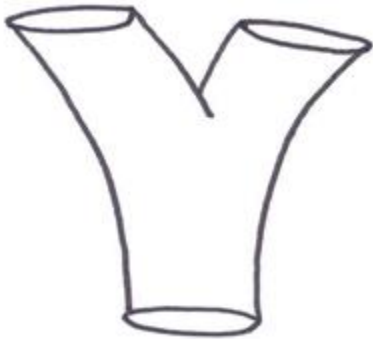Type of problem: Carotid Symptoms: Weakness _____ Numbness _____ Temporary loss of sight _____

Vertebral Symptoms: Dizziness _____ Double Vision _____ Diff. Speech _____ Diff. swallowing _____ Drop attacks _____

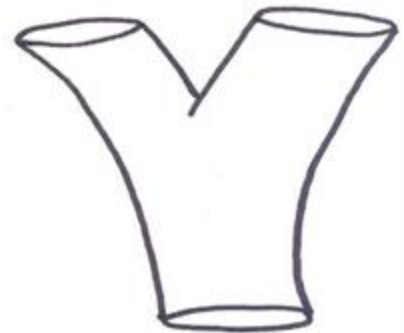
<u>Right</u>	<u>Left</u>	<u>cm/sec</u>	
		<u>Velocity</u>	<u>Stenosis</u>
CCA Velocity _____ cm/sec	_____ cm/sec	30 to 150 cm/sec	0% to 40%
		150 to 250 cm/sec	45% to 65%
		> 250 cm/sec	65% to 95%
		<u>Velocity</u>	<u>Stenosis</u>
ICA Velocity _____ cm/sec	_____ cm/sec	30 to 110 cm/sec	0% to 45%
		110 to 170 cm/sec	25% to 65%
Vertebral Art: Antegrade / Retrograde	Antegrade / Retrograde	170 to 250 cm/sec	65% to 75%
		250 to 400 cm/sec	75% to 85%
		400 to 600 cm/sec	85% to 95%
ICA/CCA Ratio: _____	_____	Less than 30 cm/sec	95% to 99%

ICA/CCA RATIOS: (<1.5 = 0 - 40% Stenosis; <1.8 = 41 - 59% Stenosis; >1.8 = 60 - 79% Stenosis; >3.7 = 80 - 99% Stenosis)

Right CCA



Left CCA



Impression:
